

SOME TAPEWORMS MAY BE A ZOONOTIC THREAT TO PEOPLE

Tapeworms such as *D. caninum* and *E. multilocularis* can infest humans.

D. caninum in humans is exceptional, but has been reported, especially in children. Humans get infested by accidental ingestion of fleas^{21, 22, 23}. Most of the time, people are asymptomatic, but mild gastrointestinal symptoms may be observed.



Although cats are less suitable hosts for *E. multilocularis* than canids, they sometimes shed oviferous segments in their faeces and therefore can participate to the life cycle of the parasite. The main source of eggs are infested foxes. The route of human infestation lies in the ingestion of plants or fruits contaminated by *Echinococcus* eggs that can persist up to several months in the environment.



In humans, alveolar echinococcosis affects the liver and is primarily characterised by an asymptomatic incubation period, which can last up to 15 years²⁴ (WHO, 2020). Later, the numerous parasite vesicles grow, invade and destroy the liver parenchyma. It causes serious morbidity. Extensive surgery and prolonged drug therapy are required. In severe cases, it may lead to death.

As faecal examination often fails at identifying tapeworm infestations, as most cats are asymptomatic, and because of the zoonotic potential of some species, tapeworm infestations must be taken into account in the regular deworming plans, based on the risk or exposure assessments.

REFERENCES

1. Labuschagne et al. (2018) Analysis of *Dipylidium caninum* tapeworms from dogs and cats, or their respective fleas - Part 1. Molecular characterization of *Dipylidium caninum*: genetic analysis supporting two distinct species adapted to dogs and cats. *Parasite*. 25:30.

2. Beugnet et al. (2018) Analysis of *Dipylidium caninum* tapeworms from dogs and cats, or their respective fleas - Part 2. Distinct canine and feline host association with two different *Dipylidium caninum* genotypes. *Parasite*. 25:31.

3. Dyachenko, V. et al. (2008) *Echinococcus multilocularis* infections in domestic dogs and cats from Germany and other European countries. *Veterinary Parasitology*, 157(3), 244–253.

4. Knapp, J. et al. (2016) Could the domestic cat play a significant role in the transmission of *Echinococcus multilocularis*? A study based on qPCR analysis of cat feces in a rural area in France. *Parasite*, 23.

5. Petavy, A. F. et al. (2000) *Echinococcus multilocularis* in domestic cats in France: A potential risk factor for alveolar hydatid disease contamination in humans. *Veterinary Parasitology*, 87(2), 151–156.

6. Umhang, G. et al. (2015) *Echinococcus multilocularis* detection in the intestines and feces of free-ranging domestic cats (*Felis s. catus*) and European wildcats (*Felis s. silvestris*) from northeastern France. *Veterinary Parasitology*, 214(1), 75–79.

7. Beugnet, F. et al. (2018) Textbook of Clinical Parasitology in dogs and cats. *Servet*.

8. Papazoglou, L. et al. (2006) Intestinal pleating associated with *Joyeuxiella pasqualei* infection in a cat. *The Veterinary Record*, 159, 634–635.

9. Wilcox, R. S. et al. (2009) Intestinal obstruction caused by *Taenia taeniaeformis* infection in a cat. *Journal of the American Animal Hospital Association*, 45(2), 93–96.

10. Little, S. et al. (2015) High Prevalence of covert infection with gastrointestinal helminths in cats. *Journal of the American Animal Hospital Association*, 51(6), 359–364.

11. Conboy, G. (2009) Cestodes of dogs and cats in North America. *Veterinary Clinics: Small Animal Practice*, 39(6), 1075–1090.

12. Barutzki, D., & Schaper, R. (2003) Endoparasites in dogs and cats in Germany 1999 – 2002. *Parasitology Research*, 90(3), S148–S150.

13. Beugnet, F. et al. (2014) Occurrence of *Dipylidium caninum* in fleas from client-owned cats and dogs in Europe using a new PCR detection assay. *Veterinary Parasitology*, 205(1), 300–306.

14. Zottler, E.-M. et al. (2019) Intestinal parasites and lungworms in stray, shelter and privately owned cats of Switzerland. *Parasitology International*, 69, 75–81.

15. Engbaek, K. et al. (1984) A survey of helminths in stray cats from Copenhagen with ecological aspects. *Zeitschrift Fur Parasitenkunde (Berlin, Germany)*, 70(1), 87–94.

16. Waap, H. et al. (2014) Parasite communities in stray cat populations from Lisbon, Portugal. *Journal of Helminthology*, 88(4), 389–395.

17. Fang, F. et al. (2015) Zoonotic helminths parasites in the digestive tract of feral dogs and cats in Guangxi, China. *BMC Veterinary Research*, 11(1), 211.

18. Hinaidy, H. (1991). Parasitosen und Antiparasitika bei Hund und Katze in Österreich – Hinweise für den Kleintierpraktiker. *Wien Tierärztl Monatsschr*, 78, 302–306, 308–310.

19. Millán, J., & Casanova, J. C. (2009) High prevalence of helminth parasites in feral cats in Majorca Island (Spain). *Parasitology Research*, 106(1), 183–188.

20. Vanparijs, O. et al. (1991) Helminth and protozoan parasites in dogs and cats in Belgium. *Veterinary Parasitology*, 38(1), 67–73.

21. Adam, A. A. et al. (2012) *Dipylidium caninum* Infection in a 41 year-old sudanese man in Nyala, Suda: The First Reported Case in Sudan in 2006. *Neel Medicine Journal*. 6(2), 37–42.

22. García-Agudo, L. et al. (2014) *Dipylidium caninum* infection in an infant: A rare case report and literature review. *Asian Pacific Journal of Tropical Biomedicine*, 4, S565–S567.

23. Sahin, I. et al. (2015) A rare cause of diarrhea in a kidney transplant recipient: *Dipylidium caninum*. *Transplantation proceedings*, 47(7), 2243–2244.

24. World Health Organization (2021) Echinococcosis. Retrieved from «https://www.who.int/news-room/fact-sheets/detail/echinococcosis»

Serviceplan | Crédits photos : iStock, Boehringer Ingelheim

TECHNICAL BULLETIN

n°2

TAPEWORMS IN CATS: WIDESPREAD BUT UNDERDIAGNOSED AND SILENTLY IMPAIRING HEALTH

Cats can be infested by several tapeworm species, the most common being *Dipylidium caninum* and *Taenia taeniaeformis*. Tapeworms are flat, segmented intestinal helminths, belonging to the class of cestodes. They are generally well tolerated, but in the absence of treatment, the parasite burden will impair the cat’s health without obvious clinical signs. Diagnosis can be challenging as tapeworm infestations are often missed by routine veterinary tests. As a consequence, their prevalence is underestimated. More importantly, some species may be transmitted to humans. Educating pet owners about the importance of prevention is key to reduce tapeworm infestations in cats.

Taenia taeniaeformis

Dipylidium caninum

TAPEWORMS ARE DISTRIBUTED WORLDWIDE

Cat infestations with *Dipylidium caninum* (feline genotype^{1,2}) or *Taenia taeniaeformis* tapeworms are common worldwide.

Echinococcus multilocularis is enzootic in foxes in some areas of the northern hemisphere. Although cats are less suitable hosts than canids, infestations have been reported^{3, 4, 5, 6}.

Dibothriocephalus latus, the “broad fish tapeworm”, is found in the lake regions of Europe: Northern Italy, Switzerland, French Alps, Hungary, and Scandinavia. Cestodes of the *Spirometra* genus are mainly found in Asia and in the Pacific Islands⁷.

Joyeuxiella and *Diplopylidium* species are geographically restricted to the Mediterranean region, Middle East and some parts of Africa.

Finally, the *Mesocostoides* spp. tapeworms are distributed worldwide but are only occasionally observed in cats.

An educational service from Boehringer Ingelheim Animal Health UK Ltd. Further information available from Boehringer Ingelheim Animal Health UK Ltd RG12 8YS, UK. ©2025. All rights reserved. Date of preparation: April 2025 UI-UI-FEL-0032-2025. Use Medicines Responsibly.

TAPEWORMS ARE ACQUIRED THROUGH THE INGESTION OF INTERMEDIATE HOSTS

Cats become infested by *Dipylidium caninum* after the ingestion of cat fleas or, very rarely lice, while grooming. All other tapeworms are transmitted through the ingestion of rodents, reptiles, birds or fishes containing larval stages. Cats are very likely to acquire tapeworms on a regular basis, due to their roaming, hunting and grooming activities. Even if indoor cats are far less exposed than free-roaming animals, they may get infested as rodents or lizards could find their way into houses.



TAPEWORMS SPECIES	INTERMEDIATE HOSTS
COMMON TAPEWORMS IN CATS	
<i>Dipylidium caninum</i>	Cat fleas (<i>Ctenocephalides felis</i>) Lice (<i>Felicola subrostratus</i>)
<i>Taenia taeniaeformis</i>	Rodents (usually mice)
RARE TAPEWORMS IN CATS	
<i>Joyeuxiella</i> spp. and <i>Diplopylidium</i> spp.	Reptiles (such as snakes and lizards)
<i>Echinococcus multilocularis</i>	Rodents (mainly voles, lemmings, field mice...)
<i>Mesocestoides</i> spp.	1 st intermediate hosts: arthropods (probably oribatid mites) 2 nd intermediate hosts: rodents, reptiles (such as lizards), and birds
<i>Dibothriocephalus</i> spp. and <i>Spirometra</i> spp.	1 st intermediate hosts: freshwater copepods 2 nd intermediate hosts: amphibians or fishes (pikes, perches, trouts...)

TAPEWORM INFESTATIONS ARE GENERALLY ASYMPTOMATIC

Adult tapeworms reside in the cat’s small intestine and are usually of low pathogenicity. Rarely, they may cause moderate intestinal disorders, such as anal pruritus, colic, diarrhoea, vomiting and variable appetite. Intestinal pleating and obstruction have scarcely been described^{8,9}. Overall, they usually impair silently the cat’s health.

Mesocestoides parasites are unusual in that the larval stage can incidentally develop in the peritoneal or pleural cavities of cats.

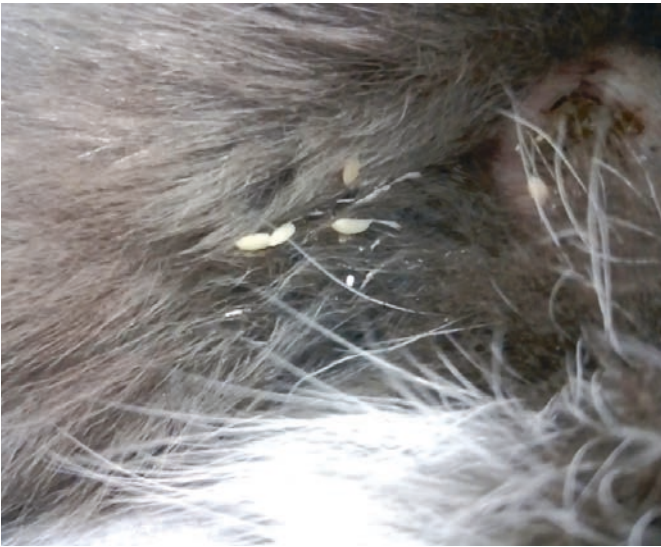This proliferation produces numerous white, semolina-like grains, in an inflammatory exudate. Clinically, the infestation can be asymptomatic, but peritonitis and ascites may occur. Diagnosis is often made by accident, during surgery.

Dibothriocephalus latus is probably the most pathogenic tapeworm. It does not only cause intestinal disorders, abdominal discomfort and diarrhoea, but it also absorbs large amounts of vitamin B12 which leads to pernicious anaemia.

DIAGNOSING TAPEWORM INFESTATION IS NOT AN EASY TASK, LEADING TO UNDERDIAGNOSIS

Proglottids are rarely present in the faeces of pets and diagnosis cannot rely on their observation.

Dipylidium proglottids actively sort out of the anus and are found in the cat’s environment: sofa, pet bedding, carpet... When dehydrated, *D. caninum* segments look like uncooked rice grains and are 3-5 mm long. When fresh, *Dipylidium* proglottids are highly motile and may cause some discomfort as they crawl actively from the anus. Perianal itching and excessive grooming of the perineum are common signs of infestation in cats.



Dipylidium caninum proglottids in the perianal region

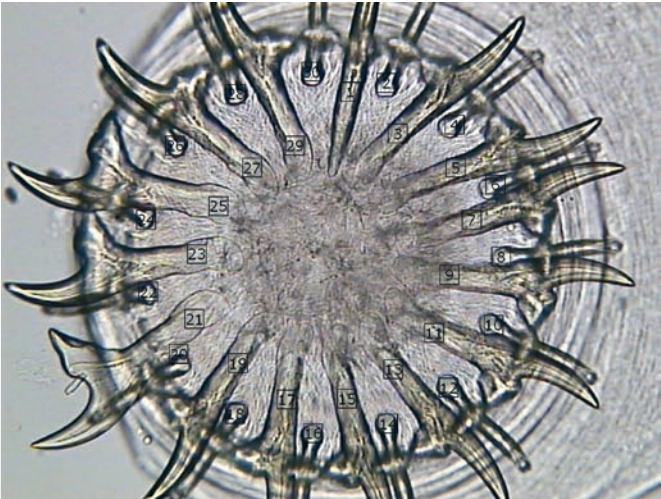
Visual observation of proglottids in cats harbouring cestodes is not a reliable detection technique¹⁰.

	PROGLOTTIDS DETECTED NUMBER OF CATS (%)
<i>Dipylidium caninum</i>	6/40 (15%)
<i>Taenia taeniaeformis</i>	6/30 (20%)

Pet owners may see tapeworm segments, also called proglottids, directly on the faeces (mainly for *Taenia*) or in the perianal region of their cats (mainly for *Dipylidium*). But in more than 80% of cases, proglottids are not observed in cats’ faeces.

Routine veterinary tests (i.e., coproscopy using flotation or sedimentation techniques) are unlikely to identify tapeworms.

Tapeworm eggs can be found in the cat’s faeces only if segments are damaged in transit or after faecal deposit¹¹. When eggs are present in the faecal material, they are not evenly distributed. Therefore, microscopical coproscopy alone is not a reliable technique to diagnose tapeworm infestations and suffers from poor sensitivity.



Taenia taeniaeformis rostellum with 30 hooks

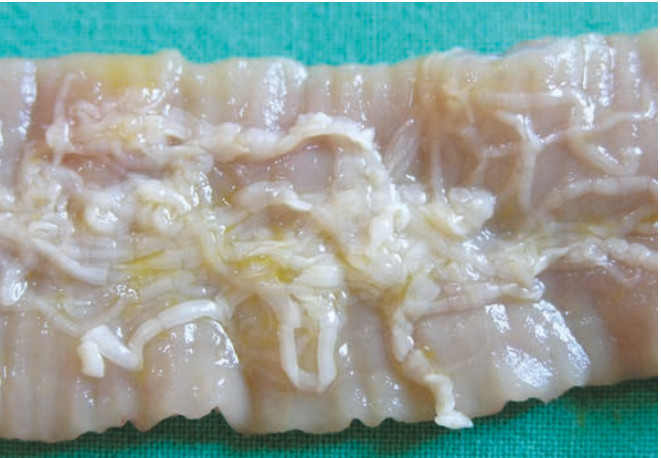In one study of over 100 cats from animal shelters, eggs were not observed by coproscopy in any cat harbouring adult *Dipylidium caninum* in the small intestine. Less than 13% of *Taenia taeniaeformis* infested cats were diagnosed through this technique¹⁰.

Flotation technique underestimates tapeworm prevalence as it may fail to identify the tapeworm presence in cats.

	PREVALENCE	TECHNIQUE
<i>Dipylidium caninum</i>	0%	Passive and centrifugal flotation technique
	34.5%	Necropsy
<i>Taenia taeniaeformis</i>	4.8%	Passive flotation technique
	12.7%	Centrifugal flotation technique
	25.9%	Necropsy

On top of that, it is impossible to make the difference between *Taenia* eggs and *Echinococcus* eggs. Given the zoonotic importance of *Echinococcus multilocularis*, it is important to identify this parasite. New techniques, based on the detection of parasite antigens (ELISA) or of specific DNA fragments (PCR) in faeces, are available to specifically detect *Echinococcus*.

Direct tapeworm recovery at necropsy examination is the most accurate method to estimate the real prevalence of cestode infestations... but is only possible in specific conditions (shelter, stray cats or wild felids).



Dipylidium caninum in cat intestine

Published data obtained through faecal examination indicate a low tapeworm prevalence, between 1.3 and 11.1%^{12, 13, 14}. Studies aiming at estimating the prevalence of cestode infestations in cats by necropsy are scarce and limited to euthanized shelter cats, dead wild felids and stray cats. Nevertheless, post-mortem examination reflects a more accurate estimate of the real prevalence of tapeworms:

- In Europe, the reported prevalence of *Dipylidium caninum* varies from 15% to 50%^{15,16}. Studies conducted in other regions of the world, such as China, reported higher rate of infestation, e.g. up to 70% in China¹⁷.
- European surveys found that 10 to 30% of cats were infested with *Taenia taeniaeformis*^{18, 19, 20}.